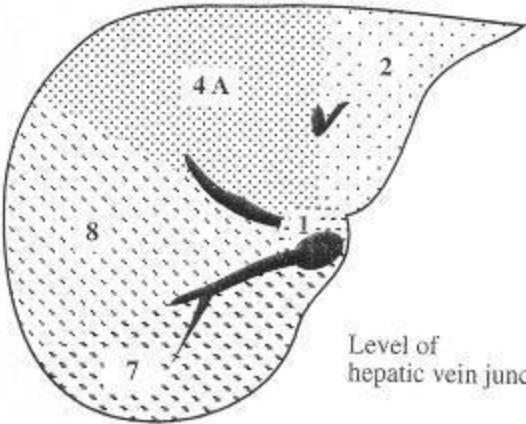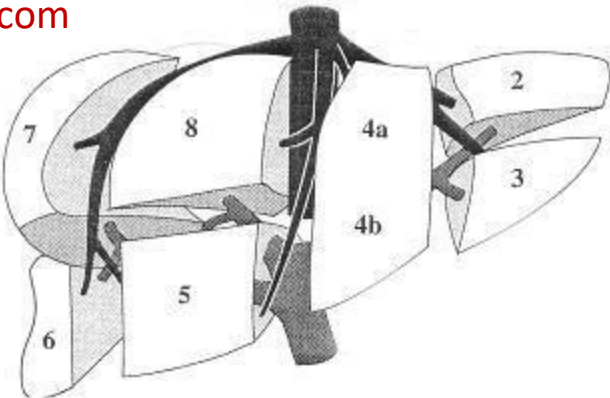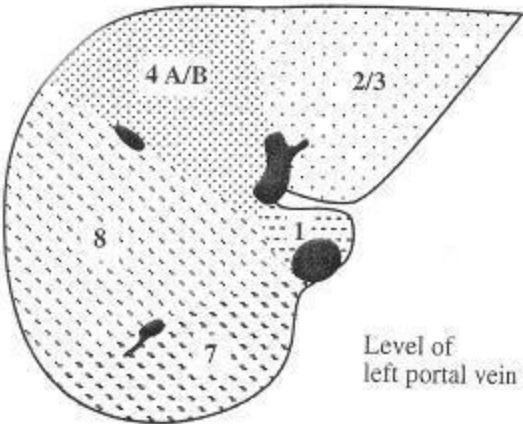
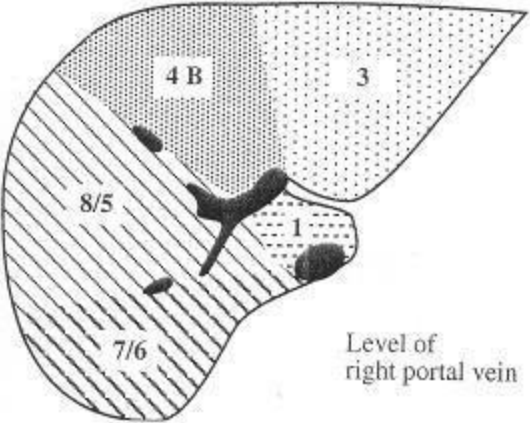


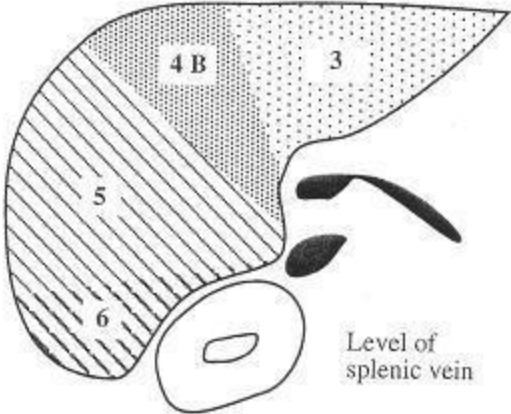
Level of hepatic vein junction



Level of left portal vein



Level of right portal vein



Level of splenic vein

Segmental liver anatomy
(REFERENCE FROM RADIOLOGY REVIEW MANUAL/WOLFGANG DAHNERT
3RD EDITION 1996)